

ORIGINAL ARTICLE

Treatment of skin laxity of the lower face and neck in older individuals with a broad-spectrum infrared light device

DAVID J. GOLDBERG^{1,2}, MUSSARRAT HUSSAIN¹, AMIN FAZELI¹ & ALEXANDER L. BERLIN¹

Skin Laser & Surgery Specialists of NY/NJ, Department of Dermatology, Mount Sinai School of Medicine, New York, NY, USA

Abstract

Background: Non-ablative approaches with infrared and radiofrequency energy sources have been shown to reduce skin laxity, but studies have focused on individuals with early-stage, mild-to-moderate degenerative dermal changes. **Objective:** The purpose of this prospective study was to evaluate the safety and efficacy of an infrared light device for the treatment of skin laxity in patients with soft tissue ptosis of the lower face and neck characteristic of the sixth decade of life and beyond. **Materials and methods:** Thirteen females, aged 58–83 years old (average: 64 years), were treated with a filtered 1100–1800 nm infrared light-based device. All individuals presented with ptotic soft tissue, but varied in the extent of skin laxity from no visible laxity to having pendulous excess skin. Two treatment sessions were provided at monthly intervals. The individuals returned for follow-up visits at 1, 3 and 6 months after the second treatment. Twelve of the individuals completed the study. **Results:** Changes were dramatic for those individuals in whom the skin envelope appeared to drape separately from deeper soft tissue. No treatment complications were noted. **Conclusion:** Infrared light source-induced skin tightening may be induced even in older individuals.

Key words: skin laxity, infrared light, cosmetic treatments of the neck

Introduction

Aesthetic re-contouring of the aging neck has traditionally entailed surgical procedures. However, surgery can preclude individuals for whom it is not medically advisable or personally desirable. Non-ablative approaches with infrared and radiofrequency energy sources have been shown to reduce skin laxity, but studies have focused on individuals with early-stage, mild-to-moderate degenerative dermal changes. It has anecdotally been suggested that patients in their sixth and later decades of life may not be the best candidates for non-invasive skin tightening.

The purpose of this prospective study was to evaluate the safety and efficacy of an infrared light device for the treatment of skin laxity in patients with soft tissue ptosis of the lower face and neck characteristic of the sixth decade of life and beyond.

Materials and methods

Thirteen females, aged 58–83 years old (average: 64 years), were treated with a filtered infrared

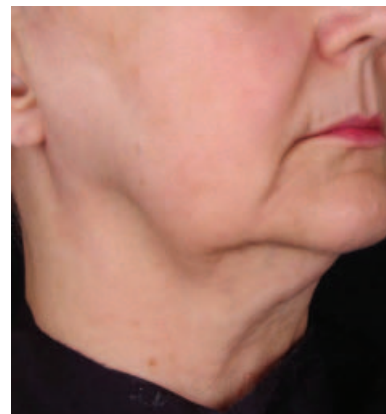

Figure 1. A 66-year-old female with soft tissue settlement in the jowls but with no apparent excess of skin.

light-based device (Titan, Cutera, Brisbane, CA, USA). The device provides dermal heating by delivering infrared light in the 1100–1800 nm wavelength range, which is absorbed by water in

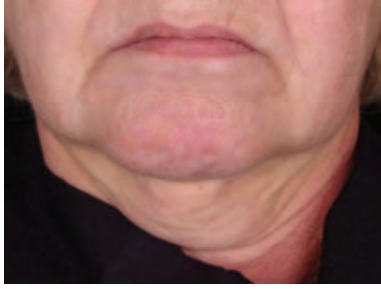


Figure 2. A 70-year-old female with loose, excess skin on the neck and fat accumulation on the face and neck.

the skin. Energy is delivered with a spot size of 1.5×1 cm and pulse durations of up to 11 seconds.

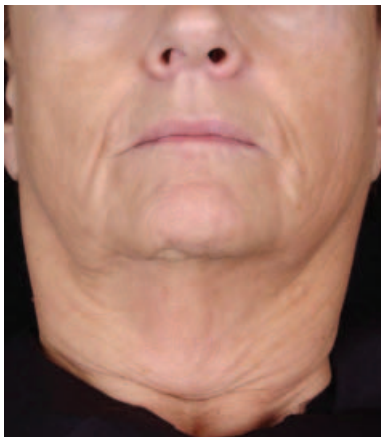All individuals presented with ptotic soft tissue, but varied in the extent of skin laxity from no visible laxity to having pendulous excess skin. They also varied in the amount of surplus fat from having no extra fat to having extensive, weighty fat deposits (Figures 1–3).

The study was undertaken under the auspices of the Institutional Review Board of Pascack Valley Hospital, Westwood, NJ, USA. All individuals

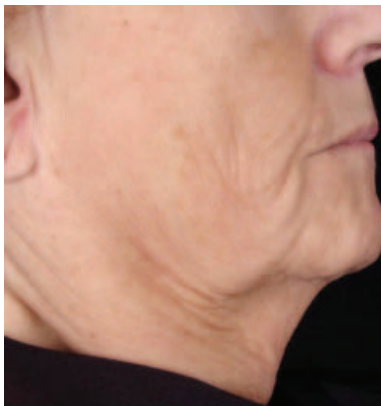received applicable informed consent. Standardized photography was utilized. All treatments were performed by one physician (AF). Treatment areas extended from the nasolabial fold to the preauricular area and from the malar prominence to the clavicle. Prior to treatment, a layer of ultrasound gel, approximately 1 mm thick, was applied to the area to be treated. Three passes of adjacent pulses were applied, with each pulse covering an area of 1.5 cm^2 . The average number of pulses applied per session was 312 (range: 230–440). Fluence was set to 36 J/cm^2 for the majority of the pulses and adjusted based on patient comfort (range: $30\text{--}36 \text{ J/cm}^2$). Pre-, parallel, and post-cooling of the epidermis to under 40°C was accomplished through continuous contact with a sapphire tip.

Additional gel was applied as needed during the treatment session. Each individual received two treatments spaced 1 month apart. The individuals returned 1, 3 and 6 months after the second treatment for photographic documentation and follow-up evaluation.

Clinical evaluations were undertaken by the treating physician. Another non-treating physician

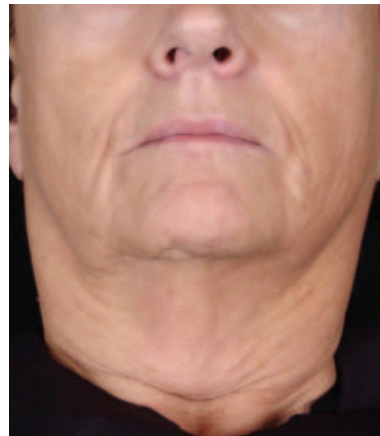

(A)

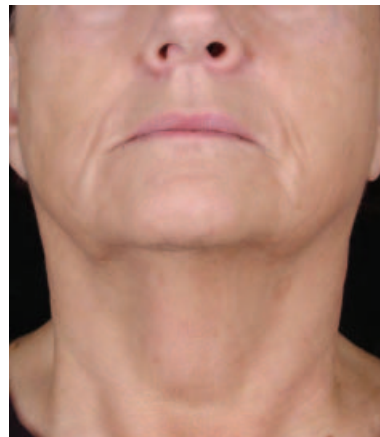

(B)

Figure 3. (A) A 64-year-old female with a large volume of excess skin on the lower face and neck; (B) Subject with a large volume of excess skin on the lower face and neck (sideview of subject shown in Figure 3a).

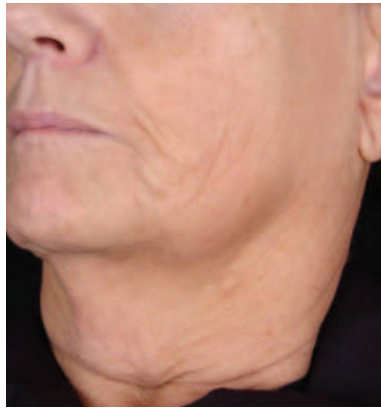

(A)

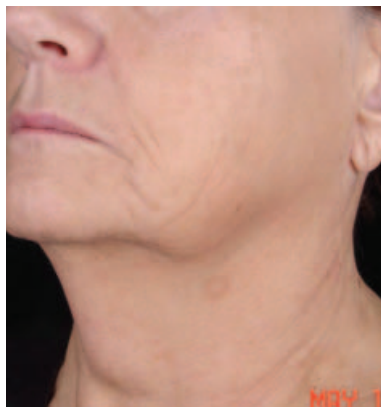

(B)

Figure 4. (A) A 64-year-old female before treatment; (B) 6 months after two treatments. Note the tightening of the jawline and neck.



(A)



(B)

Figure 5. (A) Same individual as in Figure 4 before treatment; (B) 6 months after two treatments.

(DJG) undertook independent analysis of unlabeled digital photographs.

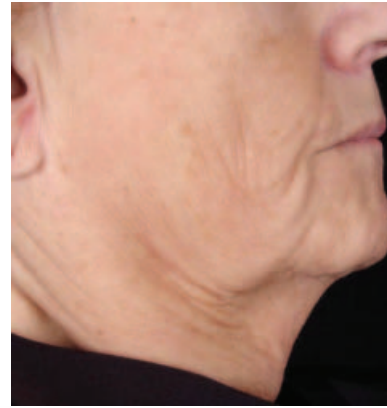Results

All treatments were well tolerated without the use of oral medications or topical anesthesia. Mild, transient erythema was the only side effect noted; no blisters or burns occurred. Erythema was seen with all individuals immediately after treatment and typically resolved within 30 minutes.

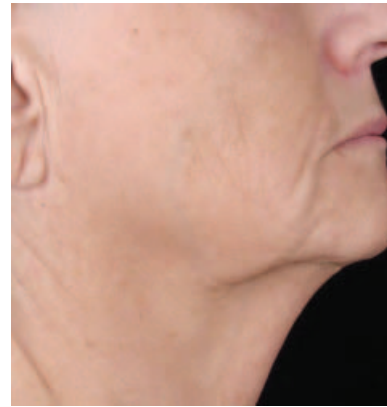Twelve out of 13 individuals kept all study visits. One individual was lost to follow-up. Clinically obvious improvement was seen in 11 of 12 individuals.

Changes were dramatic for those individuals in whom the skin envelope appeared to drape separately from deeper soft tissue (Figures 4–9). The noted changes consisted of improved mandibular definition, increased cervicomental angularity, and decreased redundancy in neck skin and/or slimming of the neck contour. Clinically observed changes coincided with those seen by the non-treating independent observer.

In those individuals in whom the skin had descended but stayed largely intact with the



(A)



(B)

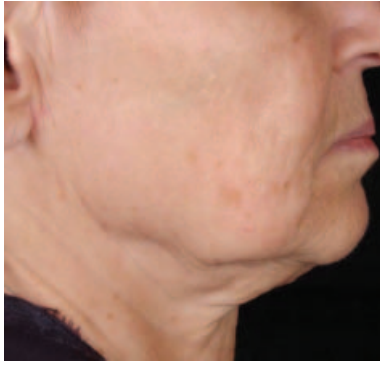Figure 6. (A) A 64-year-old female before treatment; (B) 6 months after two treatments.

subcutaneous tissue, improvement was mild to moderate (Figure 10). The one individual gaining no noticeable improvement presented with jowls formed by fat descent but no excess skin (Figure 1). Individuals continued to improve past the 1-month follow-up visit (Figures 11–13). No scars or pigmented alteration was noted.

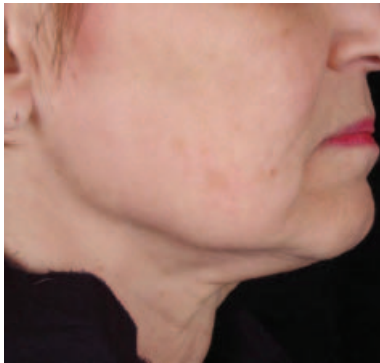Discussion

As non-invasive, non-ablative rejuvenation techniques have become more popular, non-surgical skin tightening has become another frontier in aesthetic medicine. Non-ablative monopolar radiofrequency has been successfully used for this purpose (1–4) and, until recently, has been the only such technology available on the market. Unfortunately, because of initially used high fluences that were associated with a significant delayed clinical response, and the potential risk of rare fat necrosis and scarring, other approaches have also been considered. This study utilized a new infrared device that delivers light with wavelengths between 1100 and 1800 nm, targeting water and resulting in collagen denaturation and dermal tightening.

Collagens are triple helices of polypeptide chains, held together by hydrogen bonds. As collagen is

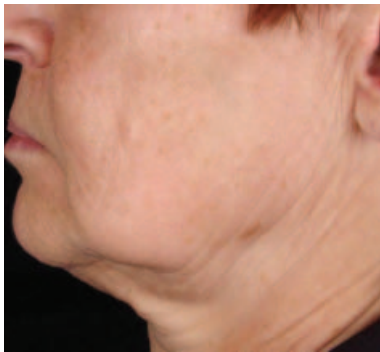

(A)

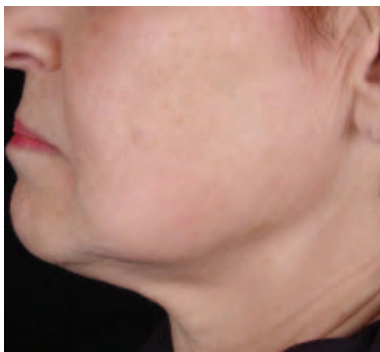

(B)

Figure 7. (A) A 61-year-old female before treatment; (B) 6 months after two treatments. Note the improvement in mandibular definition and the cervicomandibular angle.

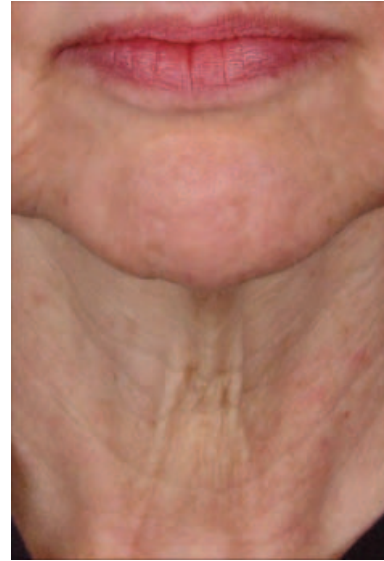

(A)

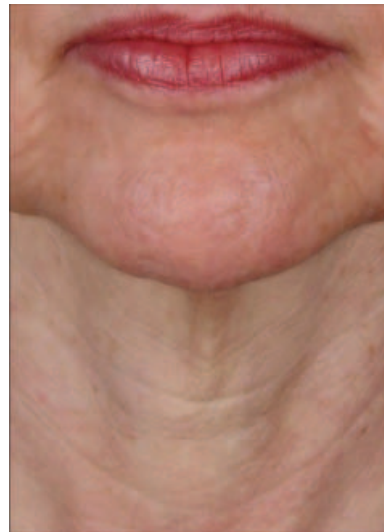


(B)

Figure 8. (A) Same individual as in Figure 7 before treatment; (B) 6 months after two treatments.



(A)

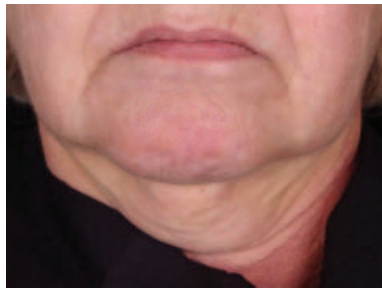

(B)

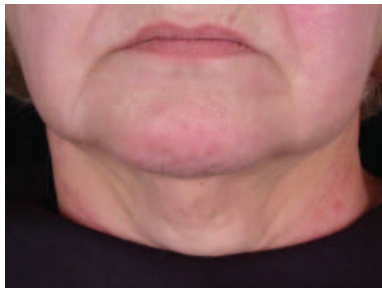Figure 9. (A) A 61-year-old before treatment; (B) 6 months after two treatments.

heated it undergoes denaturation. This process is not completely understood, but is thought to involve breakage of hydrogen bonds and a conversion from a crystalline to an amorphous state (5). This results in thickening and shortening of collagen fibrils, increased tissue tension due to the rubber-elastic properties of collagen, and, ultimately, tissue tightening (6). Higher heating temperatures, however, may be associated with liquefaction of collagen and other dermal proteins, with the resulting inability to contract and a subsequent healing process akin to scarring.

Various in vitro studies on mammalian skin suggest a thermal denaturation temperature of between 58°C and 68°C (7). More recent research suggests that collagen denaturation does not occur at a specific temperature, but rather follows a



(A)



(B)

Figure 10. (A) A 70-year-old female before treatment; (B) 6 months after two treatments. Improvement was limited by submental fat distribution.

mathematical construct known as the Arrhenius equation. According to this equation, for every 5°C decrease in temperature, a 10-fold increase in treatment duration is needed to achieve the same amount of denaturation of collagen (6). Thus, a combination of temperature and time, rather than time alone, determines the amount of collagen denaturation and tissue contraction.

Dermal water is a convenient heating tissue target, as it allows for an even distribution of heat in the treatment zone. The infrared device used in this study features a large spot size (1.5 × 1 cm) and long pulse durations of up to 11 seconds. The depth of

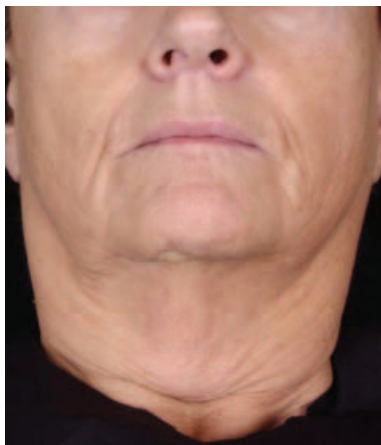heat penetration is estimated to be 1–2 mm, with some heat reaching as deep as 5 mm (8).

Because of long pulse durations, much lower fluences can be utilized with the chosen light-based device. This results in minimal discomfort. In a recent study, fluences as low as 20–30 J/cm² were used, precluding the need for topical anesthesia (8).

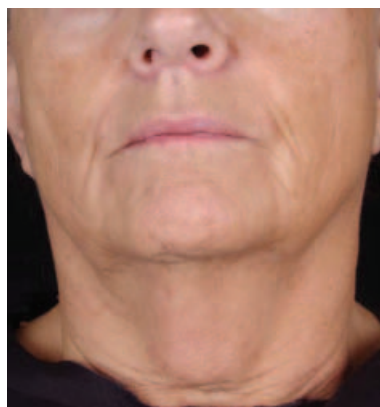
Few studies have so far evaluated the skin tightening clinical efficacy of broad-based infrared heating. In a previous study of 25 individuals, 22 experienced immediate contraction, with the persistence of clinical improvement for up to 12 months. Of note, fluences of 30 J/cm² in combination with 150–360 delivered pulses produced better clinical results when compared with fluences of 20 J/cm² with less than 150 pulses. Additionally, eight out of nine individuals in this previous study had previously been treated with a non-ablative radiofrequency device and reported equal or superior results with infrared studies (8). It should, however, also be noted that an earlier report failed to demonstrate such results (9). However, different treatment parameters were used in these studies. Recent ultrastructural analyses confirm that the degree of collagen fibril alteration was fluence-dependent with this selectively filtered infrared device. This, at least in part, may explain the differing results (10).

What remains unclear is why some treated individuals respond well to treatment, while others may not. In our non-responsive individuals, infrared heating may have contracted the lax skin, but the degree of visual impact was constrained by the small amount of excess skin relative to the underlying structure and/or the resistance of dense fat deposition.

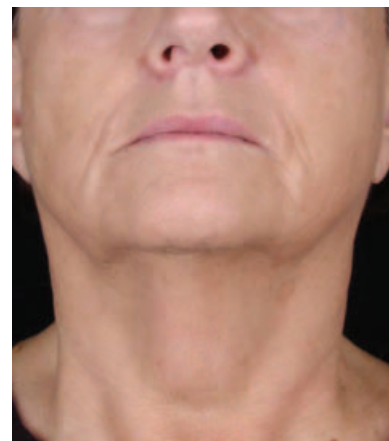This study is the first to show that non-surgical tightening of neck and jowl skin may be produced in an older population. The study also confirms the safety and efficacy of infrared light-based heating in



(A)



(B)



(C)

Figure 11. (A) A 64-year-old female before treatment; (B) 3 months after two treatments; (C) 6 months after two treatments. Note the continued improvement from 3 to 6 months after treatment.

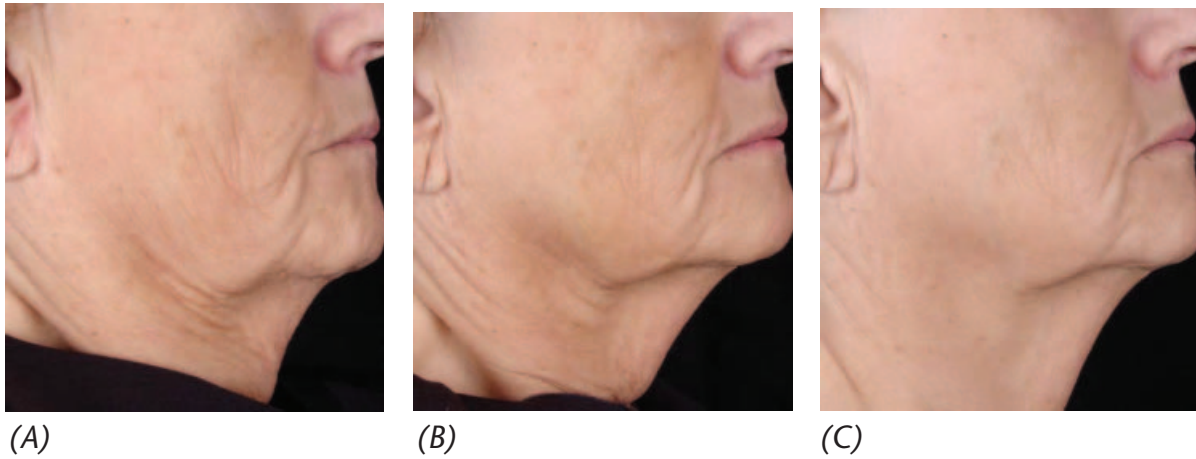


Figure 12. (A) Same individual as Figure 11 before treatment; (B) 3 months after two treatments; (C) 6 months after two treatments. Note the continued improvement from 3 to 6 months after treatment.

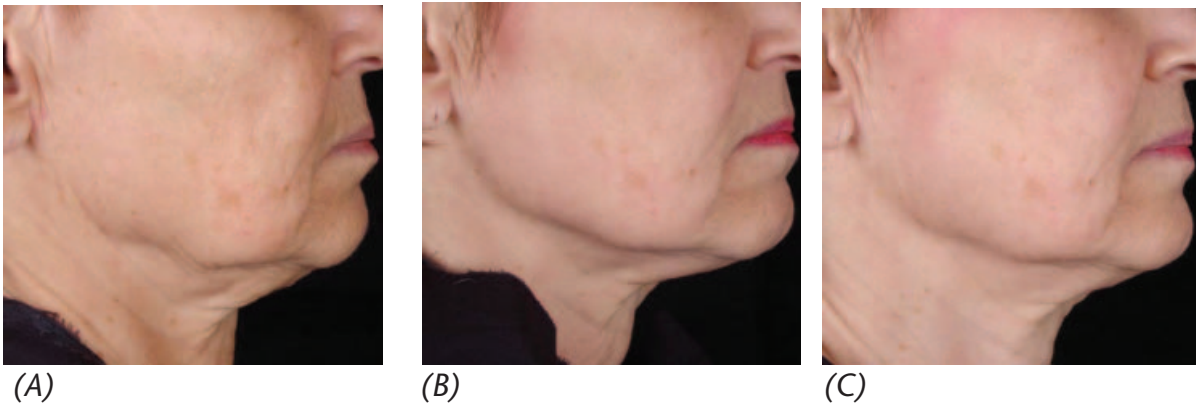


Figure 13. (A) A 61-year-old female before treatment; (B) 3 months after two treatments; (C) 6 months after two treatments. Note the continued improvement from 3 to 6 months after treatment.

the reduction of skin laxity. While the impact of non-ablative dermal tightening can be modest compared to surgical results, significant improvement in submental and submandibular definition can be accomplished. Improvement was most dramatic in those for whom loss of definition was due, at least in part, to excess skin that suspended beyond underlying structures. This study, small in size, was meant as a pilot trial. Larger series of treated individuals are required for a more detailed statistical analysis of our findings.

References

1. Goldberg DJ, Koch J, Burns J, Geronemus R. A new non-ablative radio frequency device to tighten tissue: A randomized trial comparing a single treatment to multiple treatments. *Lasers Surg Med.* 2003;32(S 15):21.
2. Alster TS, Tanzi EL. Improvement of neck and cheek laxity with a nonablative radiofrequency device: A lifting experience. *Dermatol Surg.* 2004;30:503–7.
3. Zelickson BD, Kist D, Bernstein E, Burns J, Kilmer S, Pope K. Histologic and ultrastructural evaluation of the

- effects of a radiofrequency based non-ablative dermal remodeling device. *Lasers Surg Med.* 2003;32(S 15):35.
4. Fitzpatrick RE, Geronemus R, Goldberg D, Kaminer M, Kilmer S, Ruiz-Esparza J. First multi-center study of a new non-ablative radiofrequency device to tighten facial tissue. *Lasers Surg Med.* 2003;32(S 15):36.
5. Lennox FG. Shrinkage of collagen. *Biochim Biophys Acta.* 1949;3:170–87.
6. Ross VE, McKinlay JR, Anderson RR. Why does carbon dioxide resurfacing work? A review. *Arch Dermatol.* 1999;135:444–54.
7. McClain PE, Wiley ER. Differential scanning calorimeter studies of the thermal transitions of collagen. Implications on structure and stability. *J Biol Chem.* 1972;247:692–7.
8. Ruiz-Esparza J. Near painless, nonablative, immediate skin contraction induced by low-fluence irradiation with new infrared device: A report of 25 patients. *Dermatol Surg.* 2006;32:601–10.
9. Lee M-WC. Comparison of radiofrequency vs. 1100–1800 nm infrared light for skin laxity. *Am Soc Derm Surg Abstracts, Atlanta, GA; October 27, 2005.*
10. Zelickson B, Ross V, Kist D, Counters J, Davenport S, Spooner G. Ultrastructural effects of an infrared handpiece on forehead and abdominal skin. *Dermatol Surg.* 2006;32:897–901.